


Chapter 9



Plastic Surgery

The pictures in this section are of the cases of cleft lip and palate that were surgically repaired by my colleagues and me in my general surgical unit; since there was no separate plastic surgery service in the hospital or, even in the neighborhood.

My colleagues have contributed some of these pictures from my archives. I am grateful for their contributions.

Cleft Lip and Palate, [Before and After Surgery]

Cleft lip & palate (adult) and cleft lip (child) (9.1a).

After palatoplasty and Millard's cleft lip repair (9.1b).



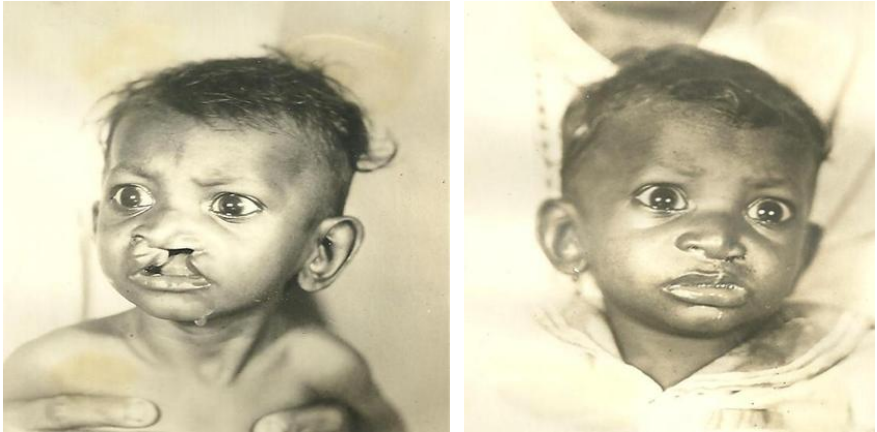
9.1a. Before surgery



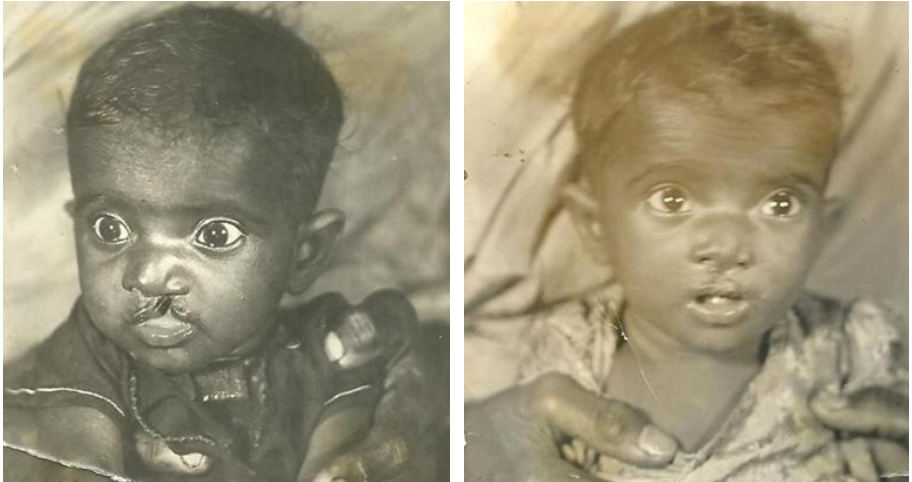9.1b. After surgery

Cleft lip & palate, pre and post repair (9.2a).

Cleft lip, pre and post repair (9.2b).



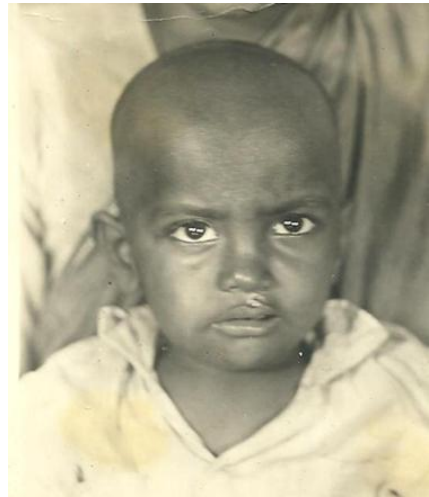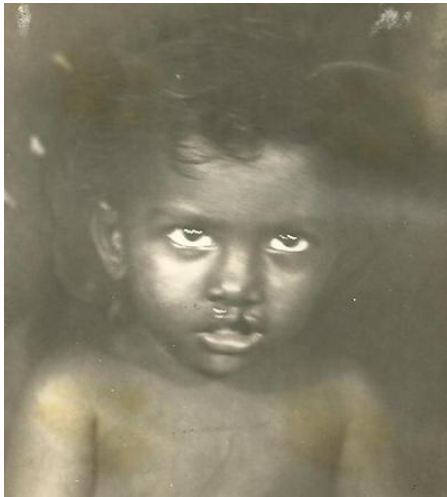9.2a



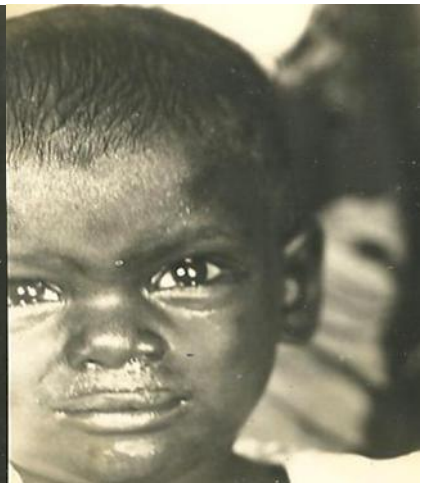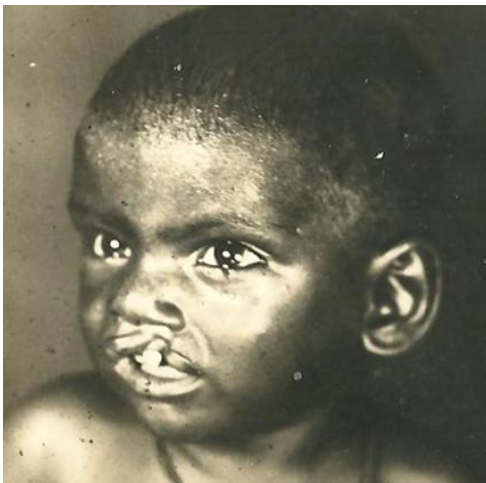
9.2b

Cleft lip, pre and post repair (9.3a).

Cleft lip & palate, pre and post repair (9.3b).

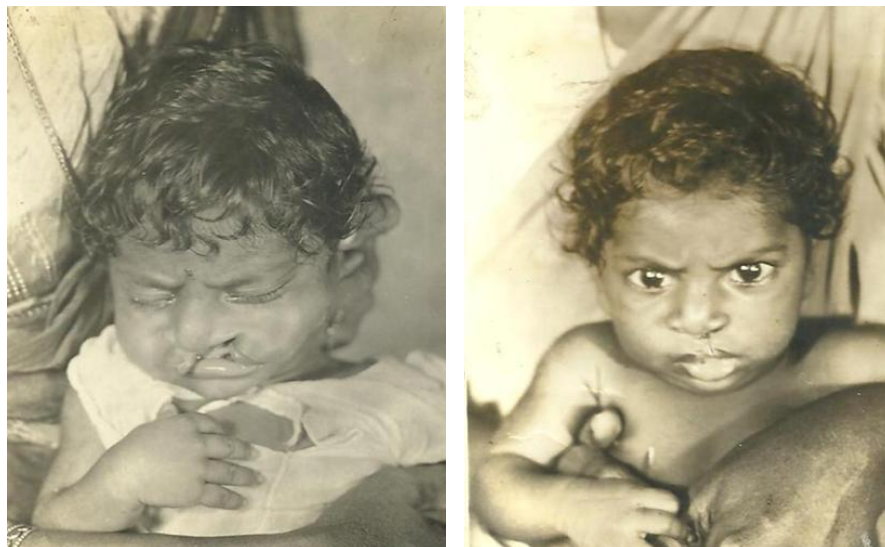

9.3a



9.3b


Cleft lip & palate, pre and post repair (9.4a).




9.4a

Cleft lip & palate, pre and post repair (9.4a).

Cleft lip, pre and post repair (9.4b).



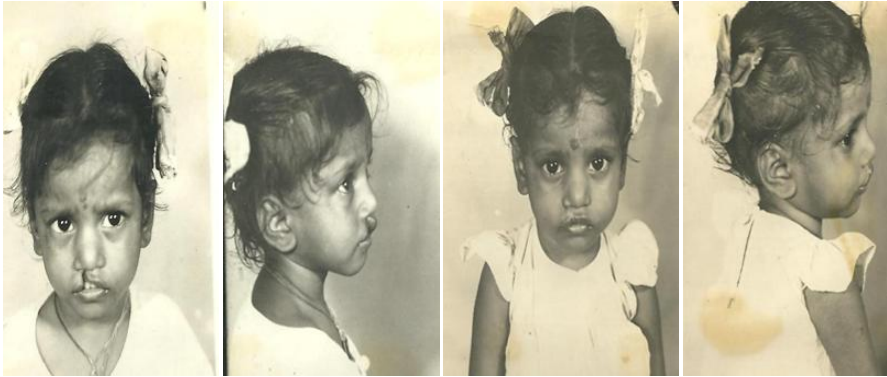9.4a



9.4b

Cleft lip, pre and post repair (9.5a).

Cleft lip & palate, pre and post repair (9.5b).



9.5a



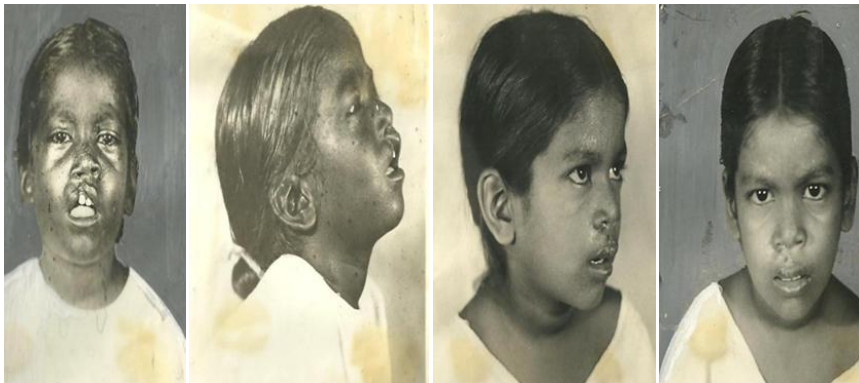9.5b

Cleft lip, pre and post repair (9.6a).

Cleft lip & palate, pre and post repair (9.6b).



9.6a



9.6b

